Clin. Otolaryngol. 2000, **25**, 378–384

Mandibular osteoradionecrosis: clinical behaviour and diagnostic aspects

G.STØRE* & M.BOYSEN†

*Departments of *Maxillo-Facial Surgery and †Otolaryngology, The National Hospital, University of Oslo, Norway*

Accepted for publication 12 April 2000

STØRE G. & BOYSEN M.

(2000) *Clin. Otolaryngol.* **25,** 378–384

Mandibular osteoradionecrosis: clinical behaviour and diagnostic aspects

We have retrospectively studied 73 patients with mandibular osteoradionecrosis (ORN) following radiotherapy (high voltage external beam radiation alone, or combined with brachytherapy) ranging from 50 to 130 Gy (mean 76) with fields including the mandible. Based on this analysis we defined four distinctive stages: Stage 0: mucosal defects only; Stage I: radiological evidence of necrotic bone with intact mucosa; Stage II: positive radiographic findings with denuded bone intra-orally; Stage III: clinically exposed radionecrotic bone, verified by imaging techniques, along with skin fistulas and infection. The clinical features and characteristics of these stages are described, along with their clinical courses and outcome. The incompleteness of current ORN definitions, mainly emphasizing mucosal defects and bone exposure, and the need for a revised ORN classification is pointed out. Based on these observations and the insufficiency of previous definitions, we arrived at the following ORN definition: Radiological evidence of bone necrosis within the radiation field, where tumour recurrence has been excluded.

Keywords *osteoradionecrosis* *mandible* *radiation*

Head and neck tumours are sensitive to radiation. Thus radiation, either delivered from an external megavoltage source, or combined with additional radioactive implantation (brachytherapy), is standard treatment–alone or combined with surgery.[1]

Osteoradionecrosis, however, is a feared complication of radiation therapy, affecting mandibular bone in the range of 2–22%.[2–5] In the early stages radionecrosis may be difficult to recognize. One difficulty encountered in obtaining exact figures of this complication is the lack of consensus on a definition of the condition in the literature. A survey of 12 published papers, in which attempts were made to define this entity, showed that the only common denominator was clinical exposure of non-vital bone.[6] This is complicated by the findings and reports of cases with an intact mucosal lining.[7,8] Furthermore, a comparison of clinical findings and outcome in various reports is difficult, due to the lack of a unified classification.

Correspondence: Geir Støre, MD, DDS, Department of Maxillo-Facial Surgery, Rikshospitalet, N-0027 Oslo, Norway.

The objective of this study was to evaluate the clinical behaviour of mandibular osteoradionecrosis (ORN). Based on this evaluation we propose a simple clinical staging as well as a new definition.

Patients and methods

The files of 73 patients (45 men and 28 women) treated for ORN in the period 1980–1998, and in whom residual tumour or recurrence could be excluded, were examined. The patients' ages ranged from 31 to 86 years (mean 60 years). All patients had received high voltage external beam irradiation (50–70 Gy) as part of the primary treatment. For 44 patients this was followed by brachytherapy (20–30 Gy) (Fig. 1). Some patients who had a residual local tumour or who developed local recurrences received a second course of radiotherapy ending up with a total dose exceeding 85 Gy. Thus the total radiation dose ranged from 50 to 130 Gy (mean 76 Gy). The time from completion of radiation therapy to the diagnosis of osteoradionecrosis was 1.5–120 months (mean 34 months). In 29 patients the tumour was located to the lateral part of the tongue, in 19 the floor of

© 2000 Blackwell Science Ltd

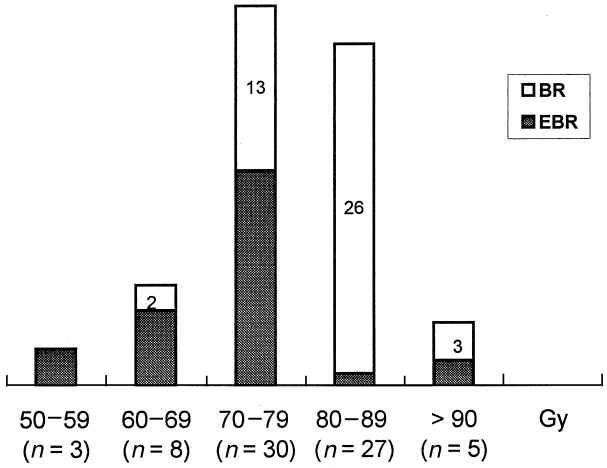

Figure 1. Range and amount of radiation given (Gy), and the ratio between cases receiving high voltage external beam radiation (EBR) alone and additional brachytherapy (BR) for 73 patients with osteoradionecrosis. (All who received a total dose exceeding 85 Gy were patients with residual tumours locally or local recurrences who had a second course of radiotherapy).

the mouth, in four the gingiva, in seven the tonsils, and in four cases the oropharynx. For the remaining 10 patients the tumour was located in the larynx, parotid gland and buccal skin, with radiation fields including a part of the mandible (Fig. 2).

One-third (24/73) had a history of trauma. Post-radiation tumour surgery involving parts of the mandible (either resection of the inner lamina or the alveolar crest) was performed in six cases. A persistent wound dehiscence, including bone exposure, following post-radiation ablative surgery was seen in three patients. In two, denture irritation causing mucosal ulcers was observed. Nine patients were edentulous.

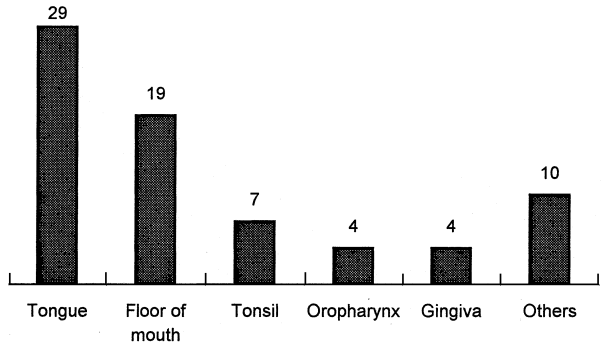

Figure 2. Distribution of the primary tumour sites of 73 patients with osteoradionecrosis.

All relevant clinical data from the initial presentation was recorded (i.e. location and extent of denuded bone intra-orally, extraoral fistula or exposed bone, suppuration, sequestrum, etc.). Furthermore, all findings from panoramic radiography as well as other imaging techniques were recorded.

The mean observation period was 4 years (range 6 months to 12 years). All patients received a conservative treatment regime of local wound care and continuous treatment with tetracyclines (currently we use Doxycyclin 100 mg daily). In cases of clinical exacerbation this dose was doubled, or a limited supplementary regime of Clindamycin, 150 mg three times daily, was prescribed.

In the follow-up period any change in clinical or radiological status was recorded. In those patients ultimately having resection, the mandibular specimen was examined histologically.

The *t*-test was used to compare the radiation dose in relation to stage of osteoradionecrosis and the χ^2 test used to compare the rate of resection according to the stage of radionecrosis.

Results

In reviewing the clinical and radiological data, four distinct stages could be defined. The group with the least changes at first presentation, had denuded bone intra-orally without any positive radiological signs. This group was incorporated because follow-up showed that the clinical changes always progressed. Further, there was a group of patients with radiological evidence of bone necrosis, but with an intact mucosal lining (Fig. 3a,b). A third group of patients had exposed non-vital bone and positive radiological signs, but without any sign of infection (Fig. 4a,b). Finally, we distinguished a group with exposed bone, purulence, extraoral draining fistula and positive radiological signs (Fig. 5a–c).

The group with mucosal defects only we called stage 0 (zero), and comprised three patients. The group with radiological evidence of bone necrosis with intact mucosa we called stage I ($n = 17$). The group with denuded bone and radiological findings ($n = 37$) we called stage II, and the group with exposed bone, radiological evidence, extraoral fistula and infection ($n = 16$) we called stage III. The end-stage and transition between stages is schematically shown in Fig. 6. All patients in stage 0 ($n = 3$) advanced into stage II. In stage I ($n = 17$) two patients developed into stage II. One patient with a spontaneous fracture healed completely. In stage II ($n = 37$), nine patients regained full mucosal coverage, ending up in stage I, while eight progressed into stage III. In five patients of stage III ($n = 16$), the suppuration ceased and fistulas healed, ending up in stage I.

There was no association between the radiation dose the patients received and the ultimate stage of radionecrosis. For stage 0 the mean dose was 98 Gy (range 85–130 Gy),

13652273, 2000, 5, Downloaded from https://onlinelibrary.wiley.com/doi/10.1046/j.1365-2273.2000.00367.x by University Of Texas Md Anderson, Wiley Online Library on [20/11/2024]. See the Terms and Conditions (https://onlinelibrary.wiley.com/terms-and-conditions) on Wiley Online Library for rules of use; OA articles are governed by the applicable Creative Commons License

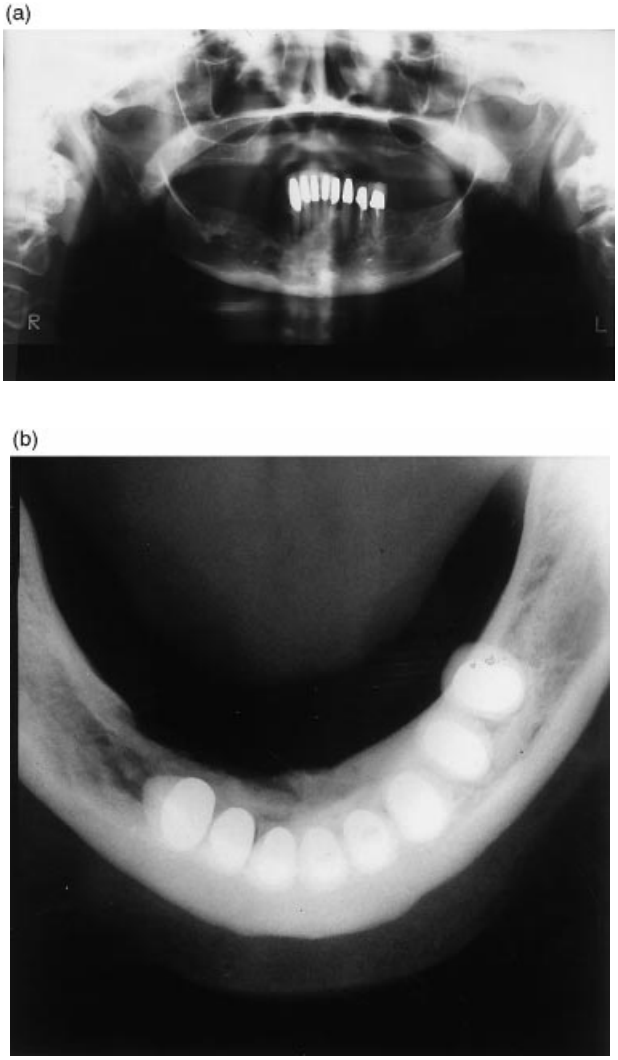

Figure 3. (a) Panoramic radiograph of female patient (age 52), showing changes in the right part of the mandible, after external beam radiation (50 Gy) followed by brachytherapy (28 Gy) for a floor of the mouth cancer. This patient had intact mucosal lining intra-orally. (b) Occlusal radiograph of same patient, showing lingual cortical bone defect.

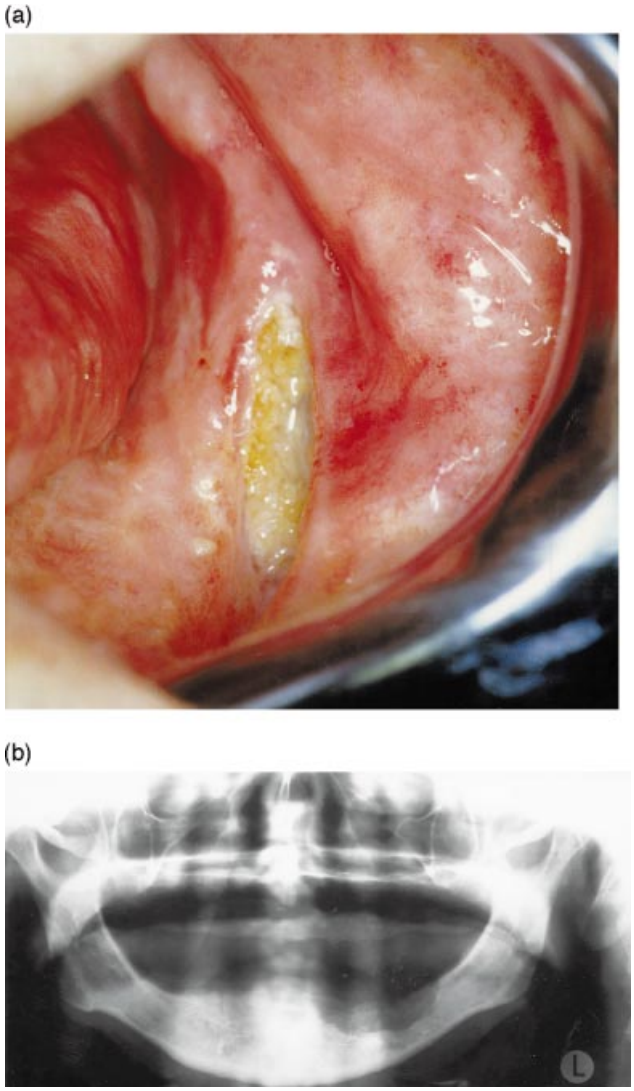

Figure 4. (a) Intraoral photo showing exposed bone of the left mandibular alveolar ridge of man (age 72), who received external beam radiation (52 Gy) followed by brachytherapy (29 Gy) for a floor of mouth cancer. (b) Panoramic radiograph of same patient, showing changes in the left mandible. Note relation to mandibular canal and alveolar nerve.

for Stage I: 76 Gy (range 64–110 Gy), for Stage II: 74 Gy (range 50–85 Gy), and for Stage III: 76 Gy (range 66–91 Gy).

For the accumulated group 1 (by the end of the observation period) ($n = 29$) only two patients needed a resection. The corresponding numbers for accumulated groups 2 ($n = 25$) and 3 ($n = 19$) were five and 14, respectively ($P < 0.05$) (Fig. 7). For the whole group, 21 (29%) ultimately had a segmental resection and loss of bone continuity, in most a hemisection of the mandible. The mean time from diagnosis of osteoradionecrosis to resection was 31.5 months (range 2 months to 12 years). The mean radiation dose to mandibles undergoing resection was 75 Gy (range 66–90 Gy). In eight patients the mandibular defect was reconstructed with a free vascular graft and in three patients with a bridging plate only. Histopathological examination of the resected bone confirmed the diagnosis in all cases.[9]

Discussion

The old truism that doctors fail to diagnose conditions of which they are unaware, is also valid for the early signs and symptoms of osteoradionecrosis. Pain and oral discomfort

13652273, 2000, 5, Downloaded from https://onlinelibrary.wiley.com/doi/10.1046/j.1365-2273.2000.00367.x by University Of Texas Md Anderson, Wiley Online Library on [20/11/2024]. See the Terms and Conditions (https://onlinelibrary.wiley.com/terms-and-conditions) on Wiley Online Library for rules of use; OA articles are governed by the applicable Creative Commons License

(a)

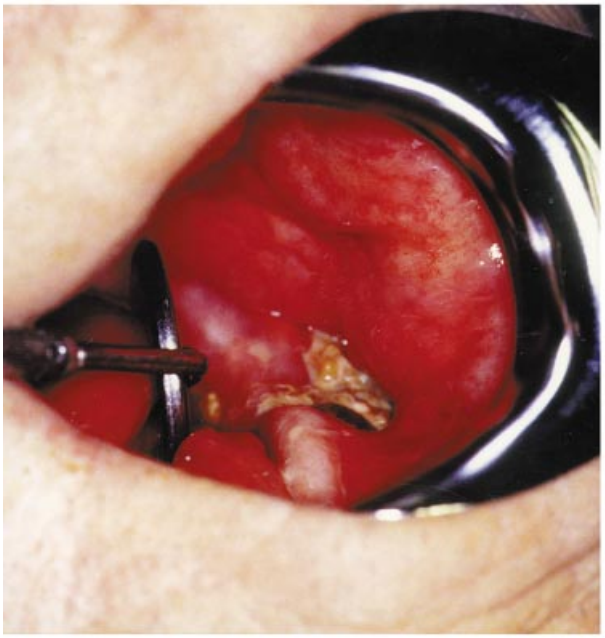

(b)

(c)

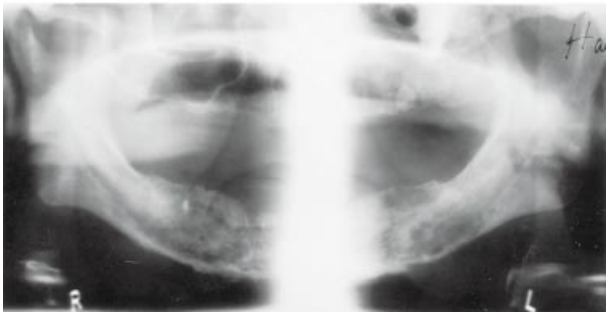

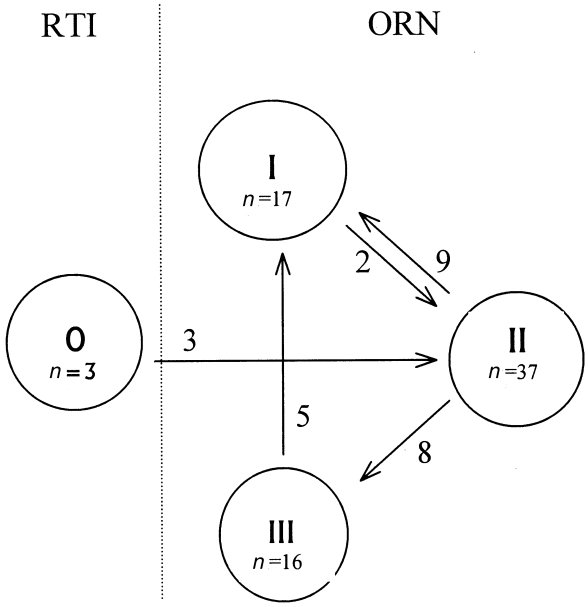

Figure 6. Diagram showing distribution of patients according to stages and transition between the stages after treatment. Stage 0 equals radiation tissue injury (RTI).

may present a diagnostic challenge in the follow-up of the irradiated head and neck patient, and exposed bone situated deeply lingually may easily be overlooked. A bone mineral loss of 30–50% is required, before it is detectable radiographically.[10,11] This may account for the relatively few cases observed in stage 0. It seems to be a transient stage, especially when appearing shortly after radiation, with a tendency to resolve spontaneously. A duration period of 3–6 months of this state, is required in most proposed definitions to qualify for the osteoradionecrotic condition.[6] Exposed bone, in a field of radiation, regardless of size and time of appearance, should be given maximum attention and care. Special concern is nevertheless associated with a late presentation, as the prospects for further deterioration are serious. All three patients in stage 0 (appearing from 12 to 64 months after radiation) progressed into stage II, with radiological signs of bone necrosis. We believe that the

Figure 5. (a) Intraoral photo showing exposed bone in left retromolar part of the mandible of man (age 72) receiving external beam radiation (70 Gy) for an uvular cancer. This patient had a new denture made for the lower jaw shortly after radiation treament, causing mucosal ulceration. (b) Same patient, showing exposed bone of the chin. (c) Panoramic radiograph of same patient, showing bilateral changes of the mandible.

13652273, 2000, 5, Downloaded from https://onlinelibrary.wiley.com/doi/10.1046/j.1365-2273.2000.00367.x by University Of Texas Md Anderson, Wiley Online Library on [20/11/2024]. See the Terms and Conditions (https://onlinelibrary.wiley.com/terms-and-conditions) on Wiley Online Library for rules of use; OA articles are governed by the applicable Creative Commons License

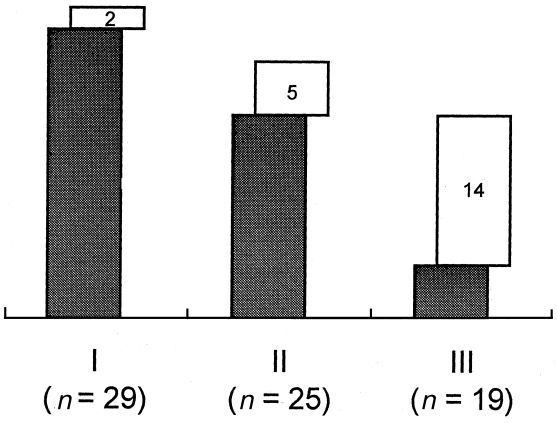

Figure 7. Diagram showing clinical outcome and accumulated groups, with the number of mandibular resections performed in each stage.

majority of patients in stage II, had stage 0 as a precursor state. A strict interpretation of the accepted term osteoradionecrosis will indicate that state 0 (zero), with its lack of positive radiological signs, should be disqualified as true osteoradionecrosis. Radiation tissue injury or mucoradionecrosis would perhaps be a more accurate term for this condition.

The classical question has for long been: is osteoradionecrosis primarily due to necrosis of the bone or the enveloping tissues? A recent study confirms the existence of an initial central bone necrosis following radiation, with loss of the spongiosa, gradually thinning and penetrating the cortex.[8] This may explain the very special pathological pattern found in stage I cases, with radiological evidence of bone necrosis, even to the degree of a spontaneous fracture, still with full mucosal coverage. One case of spontaneous fracture, but with good alignment, healed spontaneously with tetracycline cover. Stage I cases are clinically often less dramatic, with few or no symptoms. This may explain the lack of focus on such cases in the literature. To our knowledge, only one such case with fracture and intact mucosa has been reported healing after hyperbaric oxygen treatment.[7]

The cases in stage I appeared more stable with a better prognosis, as only two cases progressed into stage II. Many patients are without symptoms, especially those without a previous history of exposed bone and periosteal affection, and the need for surgical intervention seems to be infrequent. Bone necrosis in this stage can be verified by various imaging techniques. When a stage II or III is diagnosed close to the tumour site and primary radiation target, a stage I osteoradionecrosis may often be observed on the contra-lateral side of the mandible.

For stage II, nine patients regained full mucosal coverage, ending up as a chronic stage I condition. Eight deteriorated into a stage III (six of which ended up with a resection). If stage II bone is managed to be kept free of periosseous infection, a chronic steady state can be maintained for years, persistent, but nonprogressive, with surprisingly little discomfort to the patient, once periosteal irritation has ceased.

When exposed irradiated bone becomes infected superficially, the risk of involvement of deeper structures is high, ending up in a 'osteoradiomyelonecrotic' state. Guttenberg[12] proposed in 1974 the term 'septic osteoradionecrosis of the mandible' for this stage. The majority of such cases become irreversible, as expressed by the high number (14 out of 19 cases) of resections performed in stage III. However, in five cases skin fistula and mucosal defects healed. One might suspect that the higher the radiation dose the more severe the osteoradionecrosis. We found no such relationship, nor did we find any evidence suggesting that the radiation dose was related to transition between the stages.

Epstein *et al.*[13] proposed a classification based on clinical progression and outcome of the treatment (with stage I being resolved and healed cases, stage II chronic and non-progressive cases and stage III active and progressive cases). We do not think that this classification system fully covers the diagnostic aspects and the need to stage patients at first presentation, as diagnosis always precedes treatment. A proper diagnosis should be based on a true definition of the disease. The diagnosis is in many studies based on observations of bone exposure for more than 3 months.[6] Widmark *et al.*[14] defined osteoradionecrosis as 'a nonhealing mucosal or cutaneous ulcer with denuded bone, lasting for more than 3 months'. Marx[15] defined it as 'an area of exposed bone > 1 cm in a field of irradiation, that had failed to show any evidence of healing for at least 6 months'. These definitions will exclude conditions with necrotic bone, even to the degree of fracture, but with an intact mucosa and skin.

To our knowledge, no definition has yet been proposed attempting to incorporate the radiological findings. Based on our findings, it may be argued that not all cases involve exposed bone, but radiological evidence can be found in all cases. Bearing in mind that 10% of all patients with osteoradionecrosis have been reported to also have residual cancer,[16] the following definition is proposed: Radiological evidence of bone necrosis within the radiation field, where tumour recurrence has been excluded.

Reviewing the number of cases compared with the amount of Gy delivered, indicates that the risk is dose dependent. This is supported by other reports.[17,18] It also shows the effect of additional brachytherapy adding up to extremely high doses. Finally it suggests that there is no such thing as a tolerant mandibular radiation dose level. Other reports have suggested a threshold dose level at approximately 60 Gy.[4,5]

13652273, 2000, 5, Downloaded from https://onlinelibrary.wiley.com/doi/10.1046/j.1365-2273.2000.00367.x by University Of Texas Md Anderson, Wiley Online Library on [20/11/2024]. See the Terms and Conditions (https://onlinelibrary.wiley.com/terms-and-conditions) on Wiley Online Library for rules of use; OA articles are governed by the applicable Creative Commons License

The rationale for long-term use of tetracycline as antibiotic, is the fact that it is chelated by the calcium of the bone and incorporated into the bone crystals.[9,19] The slow release from bone undergoing remodelling has made it the drug of choice for aseptic clinical lesions.[19] A prophylactic dose of 100 mg daily is tolerated well by most patients.

Non-curable pain, especially when the inferior alveolar nerve becomes involved (Fig. 4b), may ultimately lead to the difficult decision for mandibular resection. In this study resection was performed in about one-third of the patients, before hyperbaric oxygen therapy was established in our Departments. This is in accordance with the study of Bedwineck,[17] who found a resection rate of 31.4%. Daley *et al.*[20] reported an overall 69.6% resection rate, which is similar to the severe group III alone, with a resection rate of 74% (14/19 cases). More studies are needed to see if hyperbaric oxygen results in lower resection numbers. The high mean radiation dose (75 Gy) found in the resection group, is supported by other studies, noting higher resection rates in patients receiving total doses > 65 Gy.[21–23]

Comparing the primary tumour sites of patients with osteoradionecrosis, two-thirds ($n = 48$) of the cases were found in radiated cancers of the tongue and floor of the mouth. The frequent use of additional brachytherapy in these cancers, may explain the high figures. With the exception of four cases of floor of the mouth cancers, the remaining floor of the mouth cases and tongue cancers ($n = 44$) in this material received brachytherapy. We have in a preliminary study reported a cohort of 68 patients with an overall incidence of osteoradionecrosis of 6%, while those cases treated with brachytherapy had a 17% incidence rate.[24] In accordance with this observation other studies have reported an up to four times higher complication rate when brachytherapy is used, compared to external radiation alone.[25–28]

Even eliminating accepted risk factors such as postradiation extractions and other iatrogenic contributions, still has shown a 3% incidence of 'spontaneous' or idiopathic osteoradionecrosis,[24] a figure that may be regarded as an 'acceptable' level of morbidity. It was believed that the advances made in radiotherapy, with megavoltage, superfractionation and new shielding techniques would abolish osteoradionecrosis as a clinical problem. As long as the need for high tumourcidal doses exist, especially in advanced head and neck cancers,[1] osteoradionecrosis will undoubtedly continue to be a clinical challenge, demanding safer diagnosis and better treatment, to improve the quality of life of these patients.

References

1 COLLINS S.L., DOUGHERTY M., STUPP R. *et al.* (1995) Head and neck. In *Clinical Oncology*, pp. 961–1022. Churchill Livingston, Edinburgh

2 EPSTEIN J., WONG F. & STEVENSON-MOORE P. (1987) Osteoradionecrosis: clinical experience and a proposal for classification. *J. Oral Maxillofac. Surg.* **45**, 104–111.

3 RANKOW R.M. & WEISSMAN B. (1971) Osteoradionecrosis of the mandible. *Ann. Otol. Rhinol. Laryngol.* **80**, 603–661

4 CHENG V.S.T. & WANG C.C. (1974) Osteoradionecrosis of the mandible resulting from external megavoltage radiation therapy. *Radiology* **112**, 685–668

5 MORRISH R.B., CHAN E., SILVERMAN S. *et al.* (1981) Osteonecrosis in patients irradiated for head and neck carcinoma. *Cancer* **47**, 1980–1198

6 WONG J.K., WOOD R.E. & MCLEAN M. (1997) Conservative management of osteoradionecrosis. *Oral Surg. Oral Med. Oral Path.* **84**, 16–12

7 VAN MERKESTEYN J.P., BALM A.J., BAKKER D.J. *et al.* (1994) Hyperbaric oxygen treatment of osteoradionecrosis of the mandible with repeated pathologic fracture: report of a case. *Oral Surg. Oral Med. Oral Path.* **77**, 461–446

8 STØRE G. & LARHEIM T.A. (1999) Mandibular osteoradionecrosis: a comparison of computed tomography with panoramic radiography. *Dento. Maxillofac. Radiol.* **28**, 295–230.

9 STØRE G. & GRANSTRøM G. (1999) Osteoradionecrosis of the mandible: a microradiographic study of cortical bone. *Scand. J. Plast. Reconstr. Hand Surg.* **33**, 307–331

10 MALSKA-WANNIEWSKA I. (1971) Microdensiometric analysis of the influence of x-irradiation on mature bone in humans. *Acta Med. Pol.* **12**, 357–338

11 GRANSTRØM G., BRÅNEMARK P.I. & KULLAA-MIKKONEN A. (1991) Diagnostic methods to evaluate the clinical and morphological responses of hyperbaric oxygen treatment in irradiated tissues. In *Proceedings of the Seventeenth EUBS, Heraklion, Greece*, pp. 423–443.

12 GUTTENBERG S.A. (1974) Osteoradionecrosis of the jaw. *Am. J. Surg.*, **28**, 438–442.

13 EPSTEIN J., WONG F. & STEVENSON-MOORE P. (1987) Osteoradionecrosis: clinical experience and a proposal for classification. *J. Oral Maxillofac. Surg.* **45**, 104–111

14 WIDMARK G., SAGNE S. & HEIKEL P. (1989) Osteoradionecrosis of the jaws. *Int. J. Oral Maxillofac. Surg.* **18**, 302–330

15 MARX R.E. (1983) Osteoradionecrosis: a new concept of its pathophysiology. *J. Oral Maxillofac. Surg.* **41**, 283–288

16 MARX R.E. (1994) Radiation injury to tissue. In *Hyperbaric Medicine Practice*, pp. 448–503. Best Publishing, Flagstaff AZ

17 BEDWINEK J., SHUKOVSKY L., FLETCHER G. *et al.* (1976) Osteoradionecrosis in patients treated with definitive radiotherapy for squamous cell carcinomas of the oral cavity and naso- and oropharynx. *Radiology* **119**, 665–666

18 RANKOW R. & WEISMANN B. (1980) Osteoradionecrosis of the mandible. *Am. Otolaryngol.* **80**, 603–661

19 COFFIN F. (1983) The incidence and management of osteoradionecrosis of the jaws following head and neck radiotherapy. *Br. J. Radiol.* **56**, 851–885

20 DALEY T.E., DRANE J.B. & MCCOMB W.S. (1972) Management of problems of teeth and jaw in patients undergoing irradiation. *Am. J. Surg.* **124**, 539–554

21 MARX R. & JOHNSON R. (1987) Studies in the radiobiology of osteoradionecrosis and their clinical significance. *Oral Surg. Oral Med. Oral Path.* **64**, 379–339

22 BEUMER J., HARRISON R., SANDERS B. *et al.* (1984) Osteoradionecrosis: predisposing factors and outcomes of therapy. *Head Neck Surg.* **6**, 819–882

23 KOKA V., DEO R., LUSINICHI A. *et al.* (1990) Osteoradionecrosis of the mandible: study of 104 cases treated by hemimandibulectomy. *J. Laryngol. Otol.* **104**, 305–307

13652273, 2000, 5, Downloaded from https://onlinelibrary.wiley.com/doi/10.1046/j.1365-2273.2000.00367.x by University Of Texas Md Anderson, Wiley Online Library on [20/11/2024]. See the Terms and Conditions (https://onlinelibrary.wiley.com/terms-and-conditions) on Wiley Online Library for rules of use; OA articles are governed by the applicable Creative Commons License

24 STØRE G. & BOYSEN M. (1993) Osteoradionecrosis of the mandible: preliminary report of a 10 year study. *Clin. Otolaryngol.* **18**, 73–77

25 PERNOT M., ALETTI P., CARLOLUS J.M. *et al.* (1995) Indications, techniques and results of postoperative brachytherapy in cancer of the oral cavity. *Radiother. Oncol.* **35**, 186–119

26 LAPEYRE M., PEIFFERT D., HOFSTETTER S. *et al.* (1997) Postoperative brachytherapy: a prognostic factor for local control in epidermoid carcinomas of the mouth floor. *Eur. J. Surg. Oncol.* **23**, 243–246

27 PODD T.J., CARTON A.T., BARRIE R. *et al.* (1994) Treatment of oral cancers using iridium-192 interstitial irradiation. *Br. J. Oral Maxillofac. Surg.* **32**, 207–221

28 LOZZA L., CERROTTA A., GARDANI DE MARIE M. *et al.* (1997) Analysis of risk factors for mandibular bone radionecrosis after exclusive low dose-rate brachytherapy for oral cancer. *Radiother. Oncol.*, **44**, 143–147

13652273, 2000, 5, Downloaded from https://onlinelibrary.wiley.com/doi/10.1046/j.1365-2273.2000.00367.x by University Of Texas Md Anderson, Wiley Online Library on [20/11/2024]. See the Terms and Conditions (https://onlinelibrary.wiley.com/terms-and-conditions) on Wiley Online Library for rules of use; OA articles are governed by the applicable Creative Commons License